

Expanding EVAR Safely

With worldwide experience and promising outcomes of the global clinical trial, it is clear the next-generation Ovation™ endograft will accommodate a wider range of AAA patients with difficult anatomy.

BY MANISH MEHTA, MD, MPH

Over the past decade, endovascular aneurysm repair (EVAR) has replaced open surgical repair at many centers as the treatment of choice for abdominal aortic aneurysms (AAAs), particularly in patients at high surgical risk. Despite the availability of six FDA-approved devices in the United States, the utility of EVAR is limited due to challenging anatomical characteristics.¹⁻⁶ Earlier studies have shown that up to 50% of patients who are considered for EVAR are ultimately denied treatment due to challenging aortoiliac anatomy such as short and complex proximal aortic necks and narrow access vessels.⁷⁻¹³ Our own experience of treating approximately 3,500 AAAs over the past decade indicates that only 65% were eligible for EVAR.¹⁴ The next generation of emerging stent grafts are evolving to accommodate difficult anatomies without sacrificing durability.

THE OVATION ABDOMINAL STENT GRAFT SYSTEM

The Ovation abdominal stent graft system (TriVascular, Inc., Santa Rosa, CA) utilizes a trimodular design with the aortic body delivered via a flexible, hydrophilic-coated, 14-F outer diameter (OD) catheter (Figure 1). The aortic body is composed of a low-permeability polytetrafluoroethylene graft and a suprarenal nitinol stent with integral anchors to achieve active fixation to the aortic wall. The aortic body contains a network of inflatable channels and sealing rings that are filled during deployment with a low-viscosity, nonembolic, radiopaque fill polymer that cures in situ to create a conformable seal to the aortic neck. The Ovation iliac limbs are comprised of highly flexible nitinol stents encapsulated in low-permeability polytetrafluoroethylene that are packaged in an ultra-low-profile 13- to 14-F OD delivery system (Figure 2). The distinguishing features of the Ovation stent graft include the smallest delivery system profile of any currently commercially available stent graft and the polymer-based sealing rings that provide a unique customized fit for each patient, including those with irregular and angulated aortic neck anatomies.




Figure 1. The Ovation Prime™ abdominal stent graft system (TriVascular, Inc.) includes a 14-F OD delivery catheter (A), fill polymer kit (B), and auto injector (C).

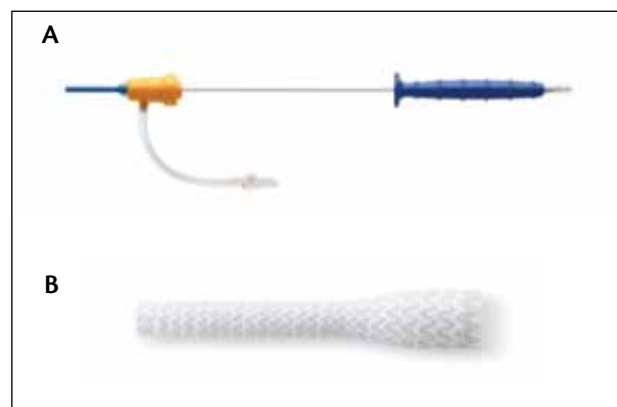

Figure 2. The Ovation Prime 13- to 14-F OD iliac limb delivery catheter (A) and flared iliac limb (B).

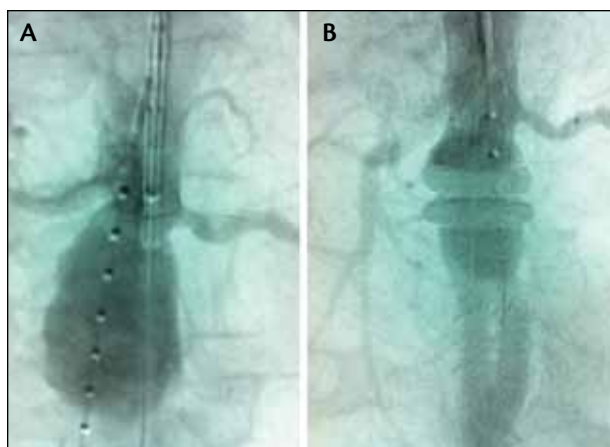


Figure 3. A preoperative angiogram shows the aneurysm (A), and a postoperative angiogram (B) demonstrates successful aneurysm exclusion with the Ovation abdominal stent graft system.

THE OVATION GLOBAL CLINICAL TRIAL

The Ovation global clinical trial enrolled 161 patients at 36 sites in the United States, Germany, and Chile. Key anatomical criteria included proximal neck length ≥ 7 mm and diameter between 16 and 30 mm; aortic neck angulation $\leq 60^\circ$ ($\leq 45^\circ$ if proximal neck length < 10 mm); distal seal zone length ≥ 10 mm and diameter between 8 and 20 mm; and AAA diameter ≥ 5 cm, 1.5 times adjacent nonaneurysmal aorta, or expansion ≥ 0.5 cm in the preceding 6 months. Importantly, challenging aortoiliac anatomy, defined as proximal aortic neck length < 10 mm and/or minimum access vessel diameter < 6 mm, was identified in 63 patients (39%) enrolled in the study.

The primary safety endpoint in the study, major adverse event rate at 30 days, was 2.5% with 0% Device Related Major Adverse Events. Treatment success, defined as technical success and freedom from AAA enlargement, type I and IV endoleaks, rupture, or conversion to open repair, was 99.3% at 1 year, with a single AAA enlargement > 5 mm reported at 1 year based on core lab (M2S, West Lebanon, NH) review of CT imaging. The investigator did not report an enlargement, but reported a type II endoleak.

The 1-year safety outcomes included a 6.2% major adverse event rate, 0.6% AAA-related mortality, and 1.9% all-cause mortality. The imaging core laboratory reported no type I, III, or IV endoleaks or stent graft migration. There were no AAA ruptures or conversions to open surgical repair, and AAA-related secondary procedures were performed in only 10 patients (6.2%) through 1 year.

It is of great interest in this study that outcomes in patients with challenging aortoiliac anatomy were impressive. In the subgroup of patients with neck length < 10 mm (Figure 3) or access vessels < 6 mm in diameter (Figure 4), there were no reports of type I or III endoleak, AAA enlargement, migration, rupture, or conversion.

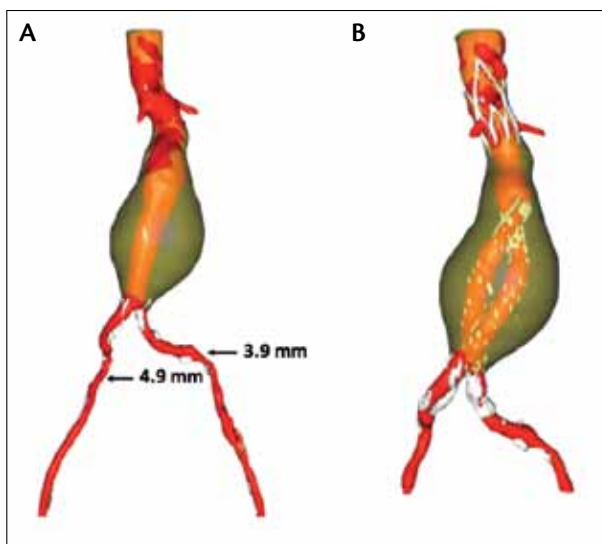


Figure 4. A CT reconstruction showing the aneurysm preoperatively (A) and successful aneurysm exclusion (B) with the Ovation abdominal stent graft system in a patient with challenging anatomy. Aortoiliac characteristics include a proximal neck length of 7 mm with thrombus and access vessel diameters of 3.9 mm (left) and 4.9 mm (right).

DISCUSSION

Stent graft technology continues to evolve at a rapid pace in order to safely expand EVAR accessibility. The Ovation endograft is a next-generation stent graft that significantly improves upon the limitations of earlier-generation devices. Historically, the most common reason for EVAR ineligibility was related to access, and therefore women have derived less benefit from EVAR when compared to men.¹⁴ Now, with the low-profile delivery catheter of the Ovation stent graft, approximately 90% of men and 70% of women with AAA have access vessel diameters amenable to endovascular repair.^{15,16} Another distinct advantage of the Ovation graft is that it is the only stent graft approved to treat proximal necks shorter than 10 mm; this feature alone might increase EVAR eligibility by about 10%.¹⁵

The Ovation aortic body is delivered via a 14-F OD delivery catheter, and the sealing rings are filled with polymer in situ. The noteworthy features include a shift in EVAR technology that utilizes the delivery system to truly uncouple the stages of stent graft fixation and seal during the procedure. This staged deployment allows for the Ovation stent graft aortic body to be packaged within a 14-F OD delivery system. The polymer-filled ring network conforms to the patient's aortic neck, creating an uninterrupted concentric seal reminiscent of O-ring or gasket-like seals that have long been considered the gold standard in other sealing applications. Further, the polymer-filled O-rings do not exert the kind of chronic outward force on the aorta that is seen with other stent graft systems that employ oversized, self-expanding stents to achieve seal in proximal aortic necks.

In the 161-patient prospective IDE study, we observed no migration, no type I or III endoleak, and no AAA rupture with the Ovation device through 1 year. To date, more than 2,500 patients worldwide have been treated with the Ovation device, many of whom were ineligible for EVAR with other stent grafts. Based on this worldwide experience and on the promising outcomes of the international clinical trial, we can conclude that the next-generation Ovation endograft is safe and effective in patients with AAA, accommodates a wider range of difficult anatomy not amenable to on-label treatment with other endografts, and expands the eligible AAA patient pool. ■

Manish Mehta, MD, MPH, is with The Vascular Group, PLLC in Albany, New York. He has disclosed that he was the national PI for the OVATION Pivotal Study, received research grants from Maquet Cardiovascular and Harvest Technologies, and has received an honorarium for speaking on behalf of TriVascular. Dr. Mehta may be reached at (518) 262-5640; mehtam@albanyvascular.com.

1. Matsumura JS, Brewster DC, Makaroun MS, Nafel DC. A multicenter controlled clinical trial of open versus endovascular treatment of abdominal aortic aneurysm. *J Vasc Surg.* 2003;37:262-271.
2. Greenberg RK, Chuter TA, Sternbergh WC 3rd, Fearnot NE. Zenith AAA endovascular graft: intermediate-term results of the US multicenter trial. *J Vasc Surg.* 2004;39:1209-1218.
3. Turnbull IC, Criado FJ, Sanchez L, et al. Five-year results for the Talent enhanced low profile system abdominal stent graft pivotal trial including early and long-term safety and efficacy. *J Vasc Surg.* 2010;51:537-544, 544 e1-2.
4. Carpenter JP. Multicenter trial of the PowerLink bifurcated system for endovascular aortic aneurysm repair. *J Vasc Surg.* 2002;36:1129-37.
5. Zarins CK, White RA, Schwarten D, et al. AneurX stent graft versus open surgical repair of abdominal aortic aneurysms: multicenter prospective clinical trial. *J Vasc Surg.* 1999;29:292-305; discussion 306-308.
6. Makaroun MS, Tuckek M, Massop D, et al. One year outcomes of the United States regulatory trial of the Endurant stent graft system. *J Vasc Surg.* 2011;54:601-608.
7. Arko FR, Filis KA, Seidel SA, et al. How many patients with infrarenal aneurysms are candidates for endovascular repair? The Northern California experience. *J Endovasc Ther.* 2004;11:33-40.
8. Armon MP, Yusuf SW, Latief K, et al. Anatomical suitability of abdominal aortic aneurysms for endovascular repair. *Br J Surg.* 1997;84:178-180.
9. Carpenter JP, Baum RA, Barker CF, et al. Impact of exclusion criteria on patient selection for endovascular abdominal aortic aneurysm repair. *J Vasc Surg.* 2001;34:1050-1054.
10. Elkouri S, Martelli E, Gloviczki P, et al. Most patients with abdominal aortic aneurysm are not suitable for endovascular repair using currently approved bifurcated stent-grafts. *Vasc Endovasc Surg.* 2004;38:401-412.
11. Moise MA, Woo EY, Velazquez OC, et al. Barriers to endovascular aortic aneurysm repair: past experience and implications for future device development. *Vasc Endovasc Surg.* 2006;40:197-203.
12. Schumacher H, Eckstein HH, Kallinowski F, Allenberg JR. Morphometry and classification in abdominal aortic aneurysms: patient selection for endovascular and open surgery. *J Endovasc Surg.* 1997;4:39-44.
13. Velazquez OC, Larson RA, Baum RA, et al. Gender-related differences in infrarenal aortic aneurysm morphologic features: issues relevant to Ancure and Talent endografts. *J Vasc Surg.* 2001;33:577-84.
14. Mehta M, Byrne WJ, Robinson H, et al. Women derive less benefit from elective endovascular aneurysm repair than men. *J Vasc Surg.* 2012;55:906-913.
15. Sweet MP, Fillingim MF, Morrison TM, Abel D. The influence of gender and aortic aneurysm size on eligibility for endovascular abdominal aortic aneurysm repair. *J Vasc Surg.* 2011;54:931-937.
16. Mehta M, Valdes FE, Nolte T, et al. One-year outcomes from an international study of the Ovation abdominal stent graft system for endovascular aneurysm repair. *J Vasc Surg.* In press.